Unusual MRI Features in a Cat with a Meningioma Mimicking a Gemistocytic Astrocytoma

Martin Deutschland[1], Kerstin Baiker[2], Daniela Denk[3]
[1]Neurological Referral Service, Berlin, Germany
[2]Pathology and Infectious Diseases, The Royal Veterinary College, Hatfield, Herts, UK
[3]International Zoo Veterinary Group Pathology, Leeds, West Yorkshire, UK
Presenting author: Dr med vet Martin Deutschland, Neurological Referral Service Berlin, Email: mdeutschland@googlemail.com, Web: www.tierneurologie-berlin.de

Signalement & Clinical history

- 13 year old male neutered Domestic Shorthair Cat
- History of intermittent hind limb ataxia, progressive episodes of anti-clockwise circling and restlessness

Clinical examination

- Physical examination: Moderate reduction of right facial sensation, right-sided ptyalism
- Blood works: Neutrophils+, Monocytes+, CK+

Magnet Resonance Imaging (MRI) Findings

- Extra-axial round parasellar lesion with regular and distinct margins, ~ 7 mm in diameter
- Extension within the mesencephalon, broad based with elevation of the cerebral peduncle
- Midline shift to right, transtentorial mass effect with secondary compression of the rostral part of the crebellar vermis
- Extension of caudal part of the cerebellar vermis towards the foramen magnum
- Extensive peri-lesional oedema (extended into the olfactory lobe and rostral cerebellar peduncle)
- T2WI: Lesion hyperintense and heterogeneous
- T1WI: Lesion isointense
- Contrast-study (T1WI): Moderate heterogeneous enhancement with mild ring enhancement. Dural tail sign was minimal and due to the location difficult to identify

MRI Scans

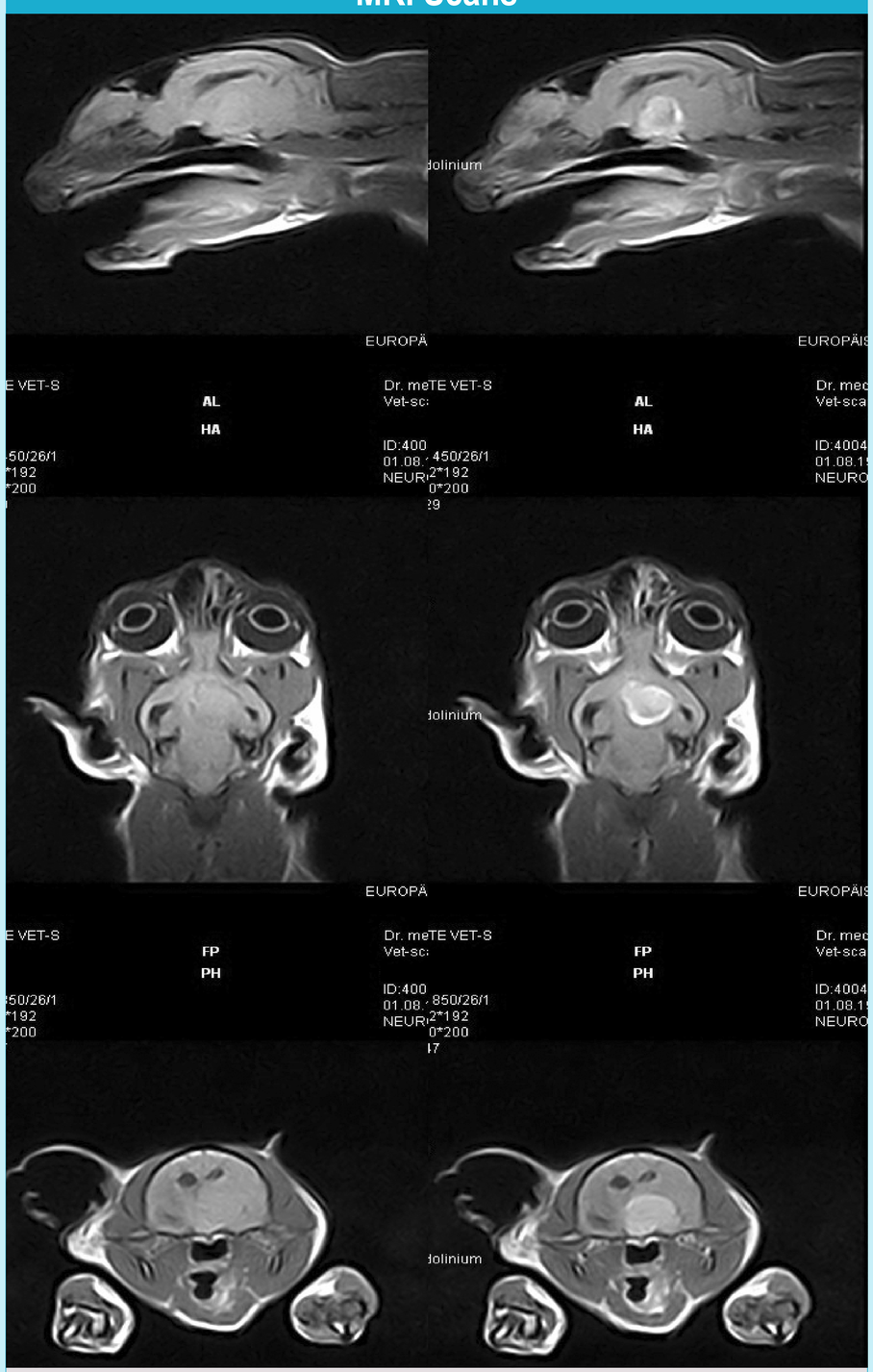

A: T1WI, sagittal, dorsal and transverse view (contrast study)

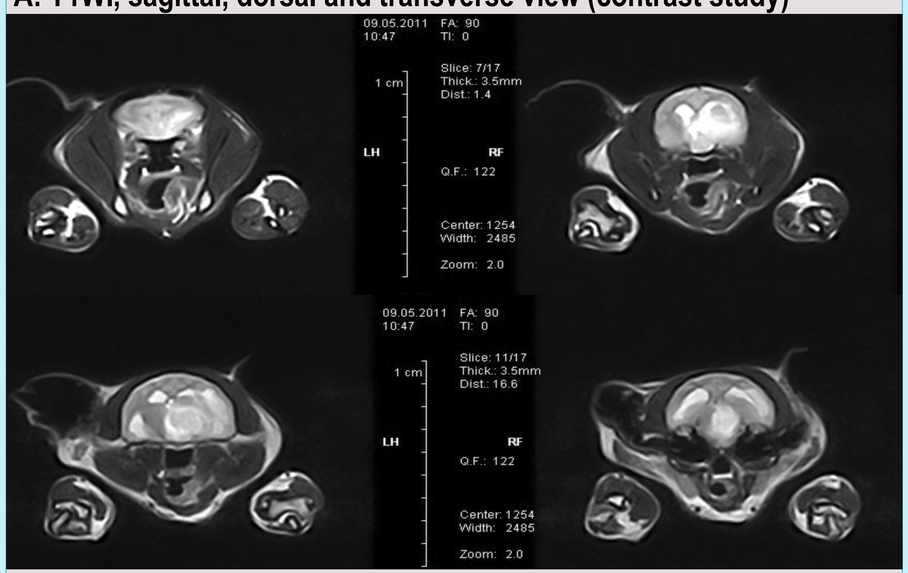

B: T2WI transversal view

Gross Pathology

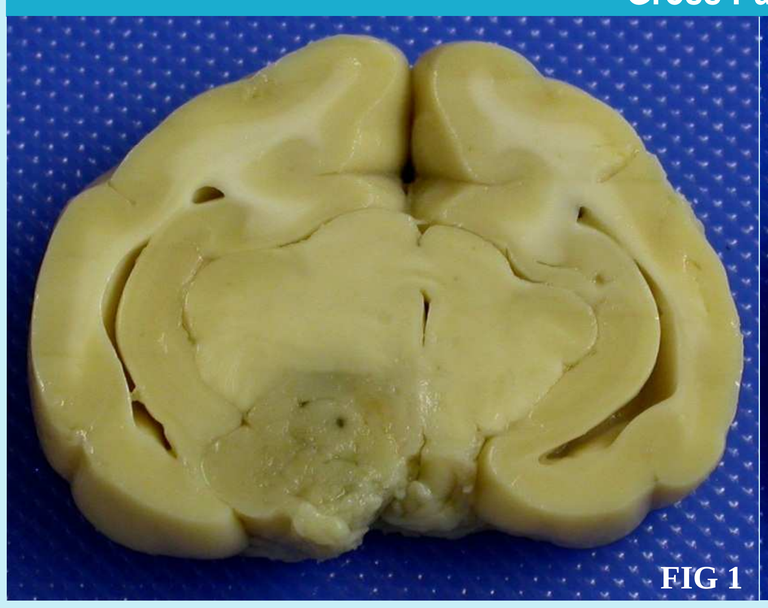

FIG 1

FIG 2

Histology and Immunohistology

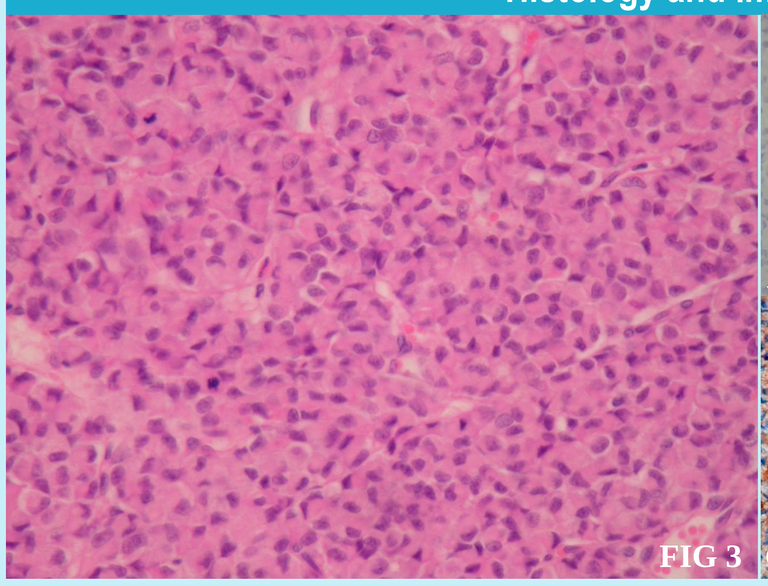

FIG 3

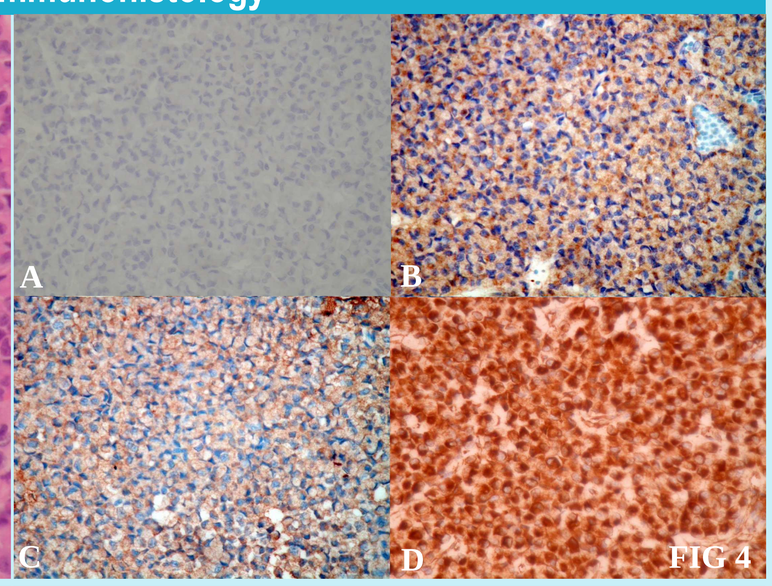

FIG 4

Localisation Meningioma Cat

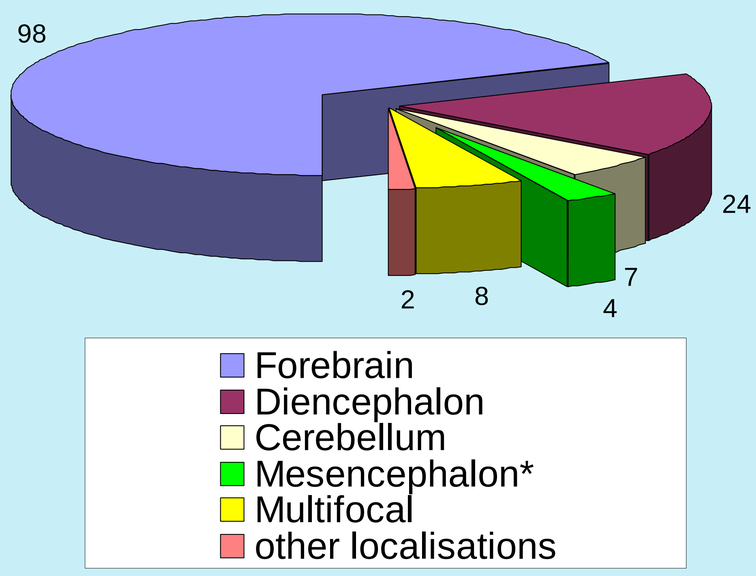

*Zaki and Hurvitz only located 2 meningiomas attenuating the brain stem

Figure Legends

- Fig 1: Well-demarcated mass in ventrolateral mes-encephalon at level of rostral collicoli & medial geniculate bodies, deviating left crus cerebri & substantia nigra, mass effect on mesencephalic aqueduct
- Fig 2: Well-demarcated mass in ventrolateral di-encephalon at level of interthalamic adhesion with prominent mass effect replacing and compressing left hypothalamic and thalamic nuclei
- Fig 3: Closely packed, angular, plumb, ~60µm in diameter tumour cells with distinct borders, abundant acidophilic cytoplasm and eccentric oval to round, partly crescent shaped nuclei with one distinct magenta nucleolus. Mild anisocytosis and anisokaryosis, no mitotic figures. H&E, x40
- Fig 4: Immunohistochemistry, x40, ABs against:
  A. GFAP: Tumour cells stain uniformly negative
  B. Pan-cytokeratin: Irregular intracytoplasmatic positive staining
  C. S100: Patchy intracytoplasmatic positivity
  D. Vimentin: Diffuse homogenous strong intra-cytoplasmatic positivity

Clinical Diagnosis, Treatment & Outcome

- MRI findings consistent with mass-like lesion (neoplasm)
- Differential diagnoses: meningioma or pituitary tumour
- Treatment: prednisolone 10mg/BID for 2 days, then once daily
- Rapid deterioration within 72 hours, euthanasia.

Pathology Results

- Tumour cell morphology closely resembles gemistocytic astrocytoma
- Immunohistochemistry with anti-GFAP negative
- Neoplastic cells positive for S100, vimentin and pan-cytokeratin ➡ diagnosis of atypical meningioma made

Literature

1 Kepes JJ. Presidential address: The histopathology of meningiomas: A reflection of origins and expected behavior? J Neuropathol Exp Neurol. 1986 Mar;45(2):95-107.
2 Tomek A, Cizinauskas S, Doherr M, Gandini, G, Jaggy A: Intracranial neoplasia in 61 cats: localisation, tumour types and seizure patterns. J Feline Med Surg. 2006;8(4), 243-53
3 Troxel M T, et al: Feline Intracranial Neoplasia: Retrospective Review of 160 Cases (1985–2001). Journal of Veterinary Internal Medicine 2003;17(6), 850-859
4 Zaki FA, Hurvitz AI. Spontaneous neoplasms of the central nervous system of the cat. J Small Anim Pract 1976;17:773–782.

Discussion

- Meningiomas within the midbrain or pituitary area are relatively rare in cats [2,3]
- So far, meningiomas mimicking gemistocytic astrocytomas have only been described in humans[1] and were seen in a very small number of dogs (unpublished personal communication, Dr Brian Summers)
- It is important to note that these unusual neoplasms should be considered as differential diagnosis for gemistocytic astrocytomas, also in cats

Acknowledgments

The authors would like to thank Dr vet med Uwe Lenk, Berlin for the referral of this case and the surgery Dr. König and his team for the support of the MRI examination. We would also like to thank the histology team of Nationwide Laboratories Leeds for their technical support. Additional special thanks goes to the RCVS histology team for the immunohistological staining.